

# Acute Intracranial Hemorrhage in Venous Thrombosis: A Mimic of Trauma in Infants

OP-045

Julie A. Mack MD, Joseph Scheller MD

# Background

- During the last decade, there have been increased number of publications questioning the reliability of the assumption

Unexplained SDH in infants\* = abusive head trauma

\*particularly when accompanied by retinal hemorrhage and brain swelling

# Lynøe et al, Systematic Review 2017

## Conclusions:

*“There is limited scientific evidence that the triad and therefore its components can be associated with traumatic shaking.”*

# The way forward

*“Publication in Acta Paediatrica does not spell the end of the discussion. Instead, it is a clear signal that more research is needed.”*

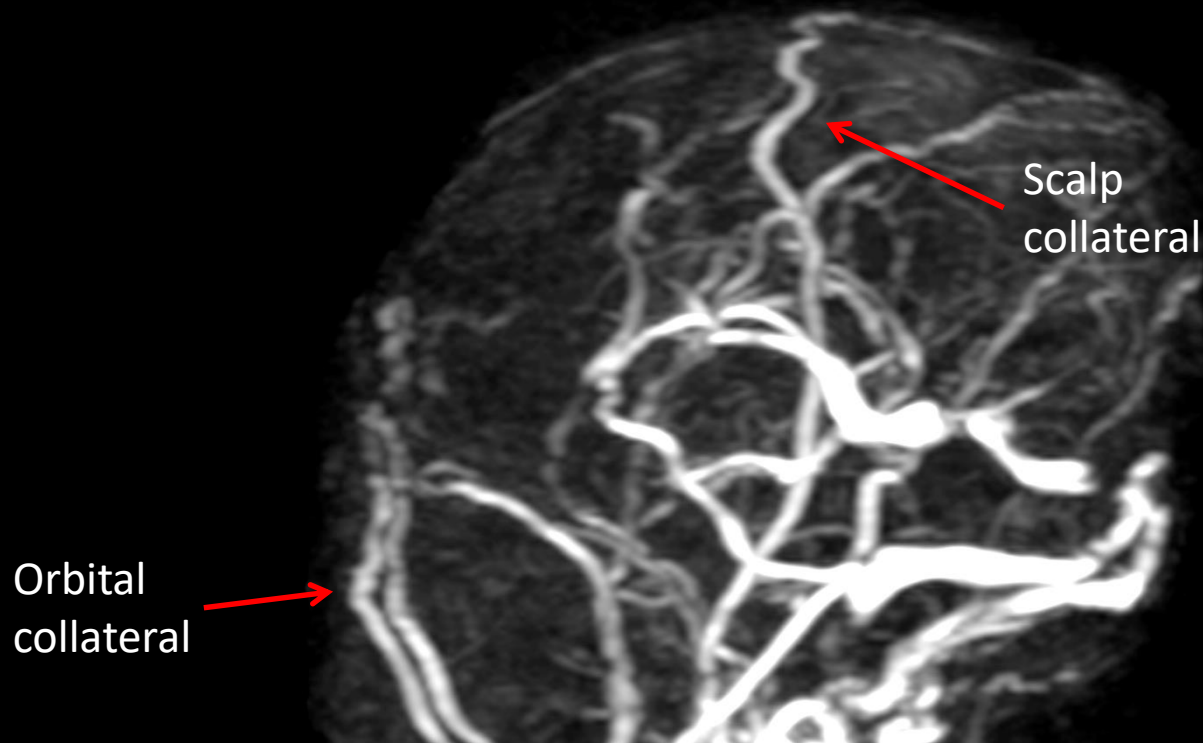
From a letter to the authors by Ludvigsson

Revisiting the association of SDH in  
venous thrombosis

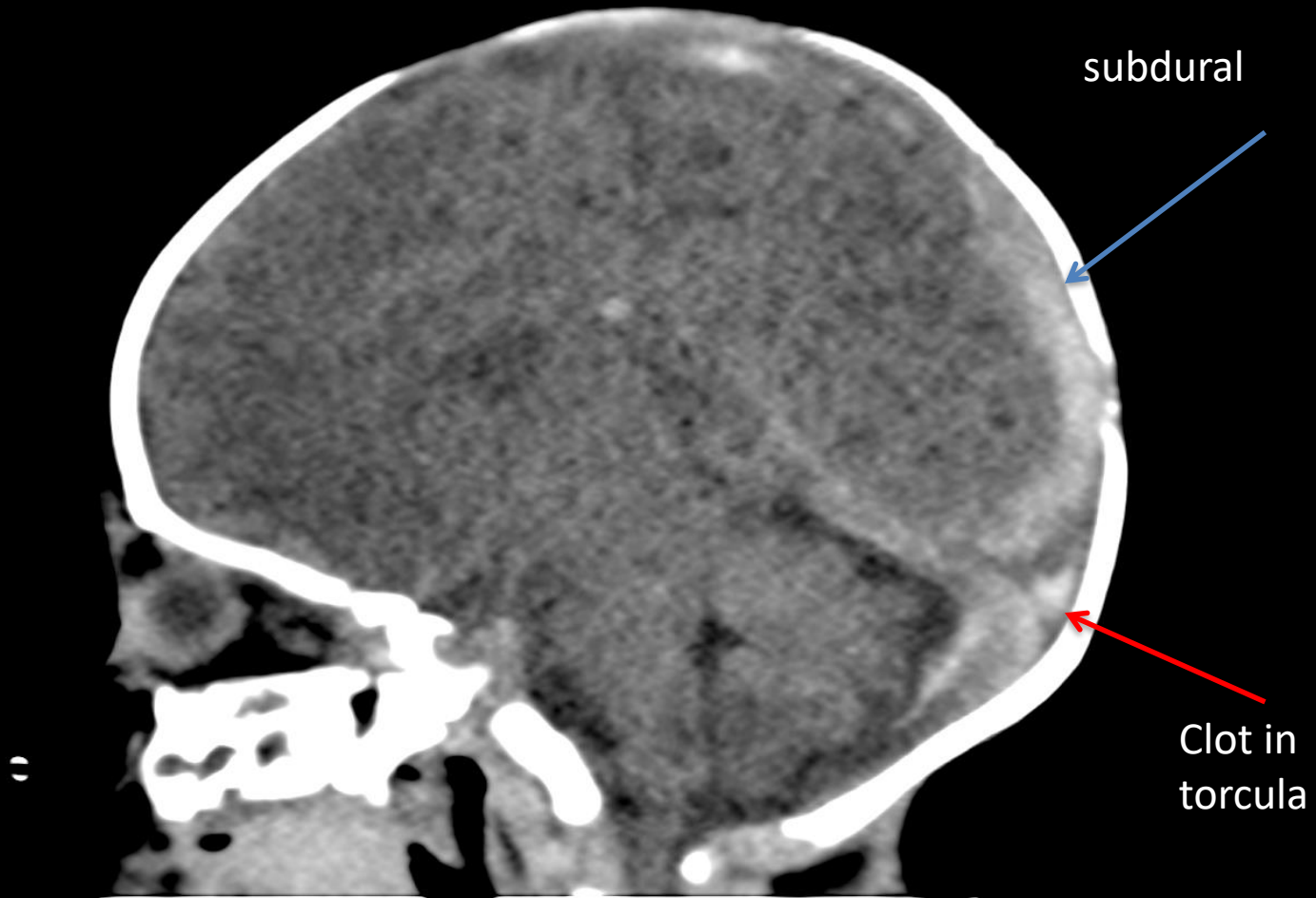
The three cases outlined in the poster were initially diagnosed with abusive head trauma based on the presence of unexplained subdural hemorrhage

All three were returned to their parents after judicial review

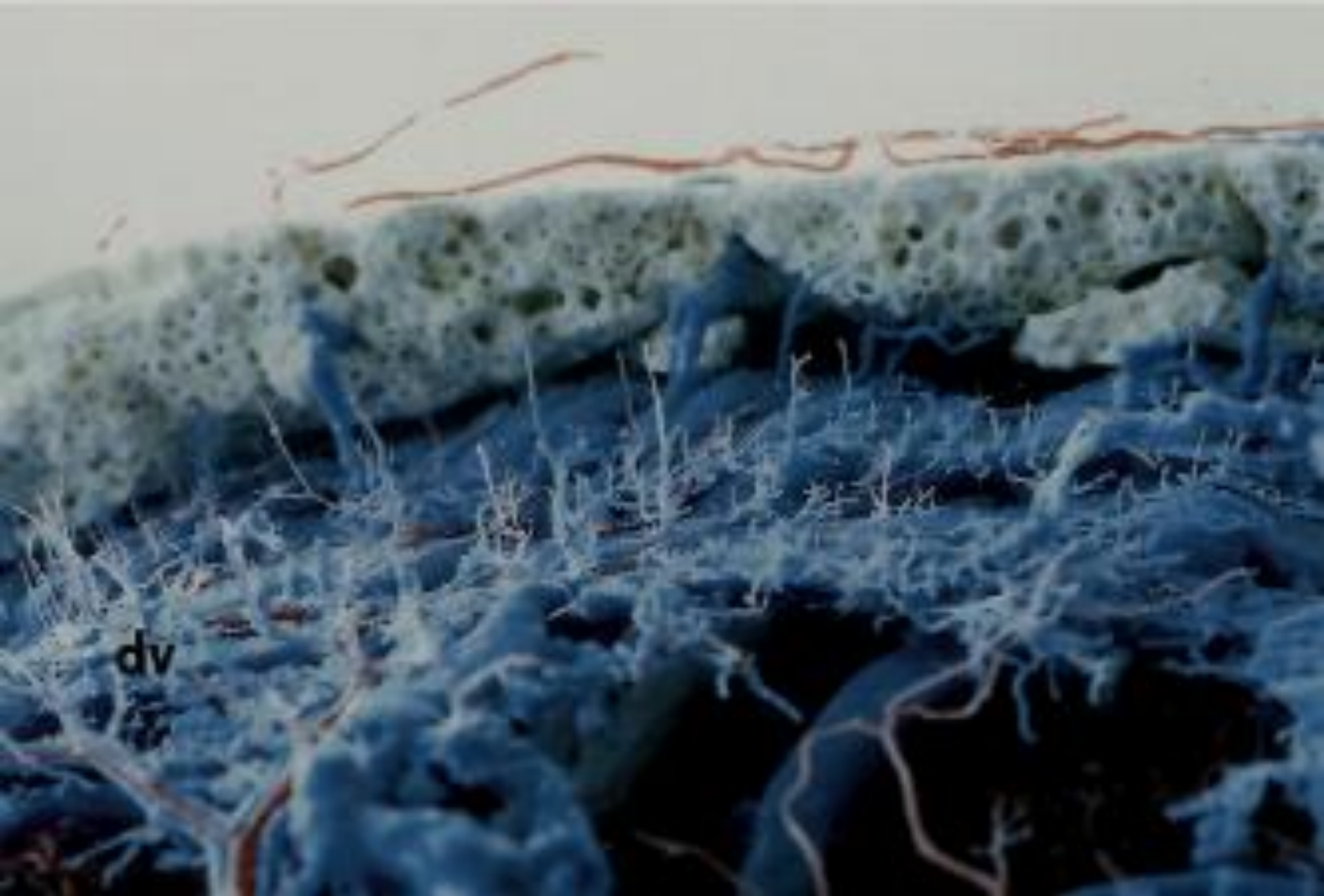
# Diffuse dural bleeding in the setting of CVT



1 month old ex premature twin with lethargy and seizures. Imaging showed SAH, SDH (blood tinged effusions), clot in the sagittal sinus extending to the torcula, and multiple thrombosed cortical veins

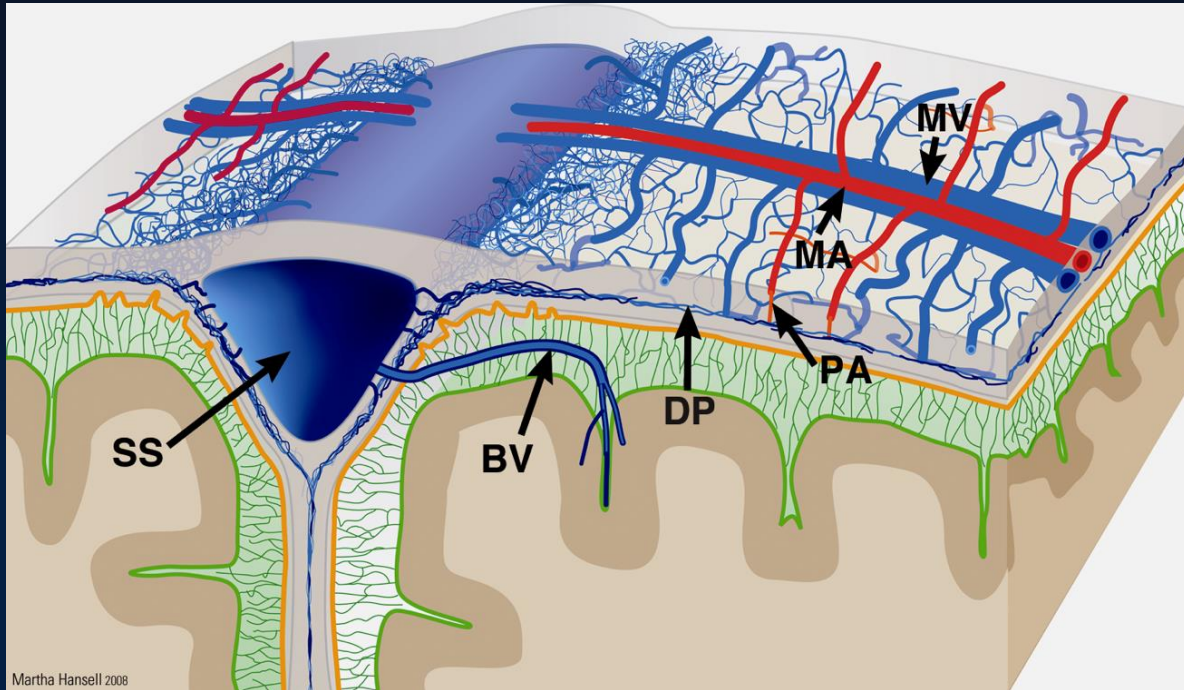


1 month old ex premature twin with lethargy and seizures





# Origin dural bleeding/effusions



Arteries, veins, capillaries in the dura are separate from the CNS. Dural capillaries do not establish a BBB, they are fenestrated and leak with neurogenic stimulation

Changes in the brain produce changes in the dural flow

# Potential etiologies of SDH in the setting of venous thrombosis

- Changes in pressure and flow resulting in bleeding and plasma extravasation from the capillaries of dura
- Increased local pressures in thrombosed veins
- Incidental bleeding from a neomembrane

# Thank you

1. Roach et al, Management of Stroke in Children. AHA Scientific Statement in Stroke 200; 39(9):2644-91
2. Diamini et al. Cerebral Venous Sinus Thrombosis in Children. Neurosurg Clin N Am. 2010; 21(3-5):511-527
3. Kaplan et al. Venous channels within the intracranial dural partitions. Radiology, 1975; 115:641-645
4. Browder et al. Venous lakes in the suboccipital dura mater and falx cerebelli of infants: surgical significance. Surg Neurol, 1975; 4:53-55
5. Scheimberg et al. Nontraumatic intradural and subdural hemorrhage and hypoxic ischemic encephalopathy in fetuses, infants, and children up three years of age. Pediatr Dev Pathol 2013; 16(3):149-59
6. Squier et al. The pathophysiology of brain swelling associated with subdural hemorrhage: the role of the trigeminovascular system. Childs Nerv Syst. 2012; 28(12):2005-15
7. Poon et al. Radiologic diagnosis of cerebral venous thrombosis: pictorial review. Am J Roentgenol 2007;189 (6Suppl):S64-75
8. Lynoe et al. Insufficient evidence for 'shaken baby syndrome'--a systematic review. Acta Paediatr 2017; Jan 27 (Epub ahead of print)